

HES: A Rare Infiltrative Hematological Disorder with Catastrophic Manifestations

Keerthy Joseph DO¹, Navyamani Kagita MD¹, Samia Hossain MD¹, Aisha Shaik MD¹, Robert Borden DO², Rajesh Thirumaran MD³

¹Mercy Catholic Medical Center Department of Medicine, ²Mercy Catholic Medical Center Department of Radiology, ³Mercy Catholic Medical Center Department of Hematology & Oncology

Case

A 68 year old woman with underlying hypertension and diabetes presented with chest pressure and exertional dyspnea for 2 days, along with progressively worsening dysphagia for 1 week. Labs showed elevated troponin of 6.73 ng/mL (peaked at 13 ng/mL), and leukocytosis with 36,000 WBCs and 52% eosinophils. EKG showed ST depressions in leads V2-V5 (Figure 1). CT chest revealed circumferential thickening of the esophagus. Heparin drip was started for NSTEMI. Cardiac catheterization did not reveal CAD. Patient developed a left sided facial droop on second day of hospitalization; brain MRI (Figure 2) showed multiple areas of restricted diffusion, concerning for embolic stroke versus vasculitis. Telemetry did not reveal any arrhythmias.

To assess for intracardiac thrombus, cardiac MRI was obtained, which revealed diffuse subendocardial hypoperfusion involving the left ventricular and papillary muscles, consistent with ischemia (Figure 3). Hypercoagulable and vasculitis workup was negative. Bone marrow biopsy showed hypercellular bone marrow with marked increase in eosinophils (Figure 4); flow cytometry revealed 45% eosinophils without an increase in other cell lineages. JAK2 V617 mutation and PDGFRA/PDGFRB/FGFR1 rearrangements were not detected. Idiopathic hypereosinophilic syndrome (HES) was deemed to be the etiology of her multi-organ damage with eosinophilic infiltration causing myocarditis, stroke, and esophagitis.

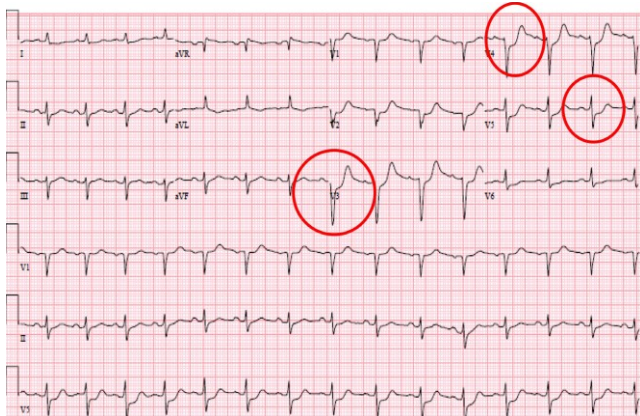


Figure 1: EKG showing ST depressions in V2-V5.

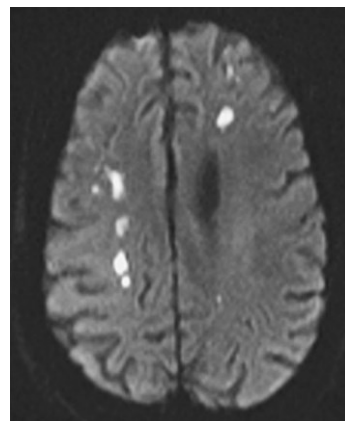


Figure 2: Brain MRI showing multiple areas of restricted diffusion.

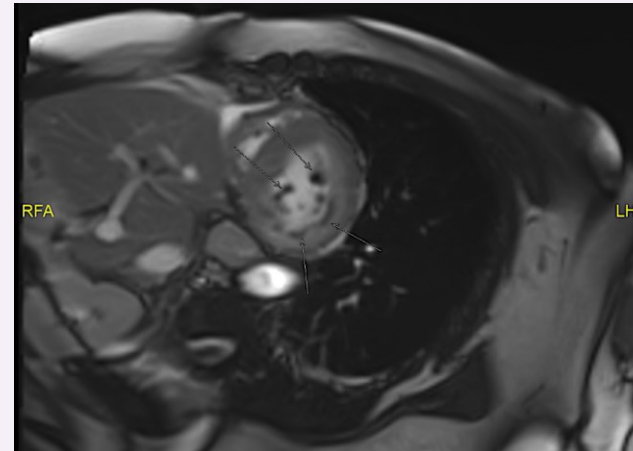


Figure 3: Cardiac MRI showing diffuse subendocardial hypoperfusion and delayed enhancement in multiple vascular territories involving the left ventricular wall and papillary muscles.

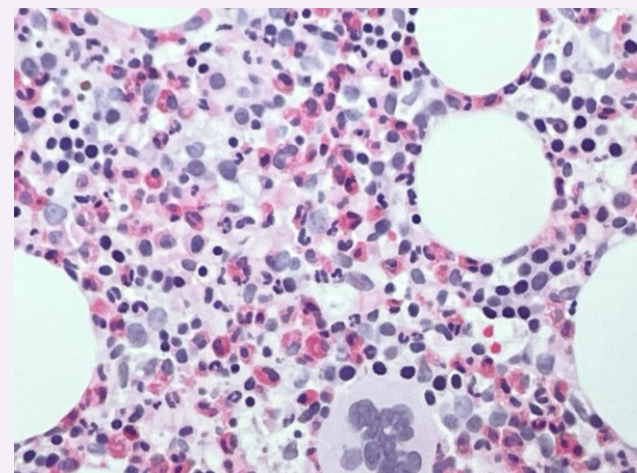


Figure 4: Bone marrow biopsy showing hypercellular marrow with hypereosinophilia.

Discussion and Conclusion

HES is a very rare clinical entity; its estimated prevalence in US is between 0.3 and 6.3 cases per 100,000 person-years. HES is characterized by elevated eosinophil count >1500 cells/microL in peripheral blood and subsequent organ damage, mediated by rapid monoclonal proliferation of eosinophils and excessive production of eosinophilopoietic cytokines, such as IL-5. HES has several variants. Myeloid variants are often secondary to PDGFRA/PDGFRB/FGFR1 rearrangements or JAK2 mutations. T cell lymphocytic variants are secondary to aberrant IL-5 producing T cells. Additionally, there are idiopathic HES, familial HES, and organ-restricted HES.

Initial studies comprise blood chemistries, IgE levels, LDH, serum tryptase, and stool testing for parasites. Further workup with echocardiogram, chest/abdominal CT, and tissue biopsies is recommended to evaluate for end-organ damage. Bone marrow aspirate and biopsy should be assessed for morphology and cellularity, followed by molecular testing for gene mutations and rearrangements. Initial therapy depends mainly on the variant of HES and manifested clinical symptoms. Myeloid variants with PDGFR mutations are initially treated with imatinib mesylate, while systemic steroids are the initial therapy for all other types of HES. Second line agents include IL-5 monoclonal antibodies (i.e., mepolizumab) to downregulate eosinophilic maturation and activation and hydroxyurea to suppress eosinophilopoiesis. Hematopoietic cell transplantation is utilized for refractory cases.

References

- Ackerman SJ, Bochner BS. Mechanisms of eosinophilia in the pathogenesis of hypereosinophilic disorders. *Immunol Allergy Clin North Am*. 2007;27(3):357-375. doi:10.1016/j.iac.2007.07.004
- Kuang FL, Klion AD. Biologic Agents for the Treatment of Hypereosinophilic Syndromes. *J Allergy Clin Immunol Pract*. 2017;5(6):1502-1509. doi:10.1016/j.jaip.2017.08.001
- Klion AD. How I treat hypereosinophilic syndromes. *Blood*. 2015;126(9):1069-1077. doi:10.1182/blood-2014-11-551614
- Klion AD, Bochner BS, Gleich GJ, et al. Approaches to the treatment of hypereosinophilic syndromes: a workshop summary report. *J Allergy Clin Immunol*. 2006;117(6):1292-1302. doi:10.1016/j.jaci.2006.02.042
- Weller PF, Bubley GJ. The idiopathic hypereosinophilic syndrome. *Blood*. 1994;83(10):2759-2779.